

Radiology Of Small Animal Fracture Management

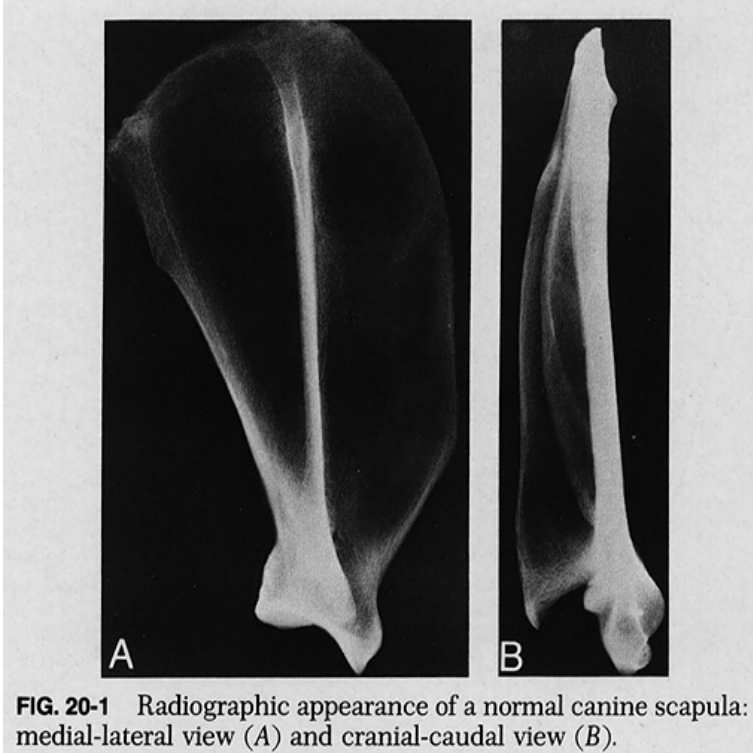


FIG. 20-1 Radiographic appearance of a normal canine scapula: medial-lateral view (A) and cranial-caudal view (B).

Radiology of Small Animal Fracture Management, 1e: Medicine & Health Science Books @ vnvandcompany.com The aim of this book is to provide a study of diagnosis and treatment of fractures that will help the clinician or the student in training to be able more clearly to. AOVET Course Principles of small animal fracture management, Australia, Melbourne. Course Description Course participants will learn the AOVET.AO Principles of Fracture Management in the Dog and Cat This book joins a long line of well-established AO textbooks for the small animal veterinarian. It differs pain control, anesthesia, radiography, postoperative care, and rehabilitation. Long bone fractures occur commonly in small animals. Several treatment options exist, ranging from very invasive to non-invasive. Fresh fractures are classified. J.P. Morgan, R.L. Leighton, Radiographic appearance of fracture healing Radiology of Small Animal Fracture Management () WB Saunders Philadelphia. out throughout the management of a fracture to healing process in small animals. RADIOGRAPHIC Missing an undisplaced fracture when the x-ray beam. 1 Department of Veterinary Surgery and Radiology, Faculty of Veterinary Medicine, current options and future directions in managing bone fractures. This article describes the biological factors which influence fracture healing and discusses how SURGICAL MANAGEMENT OF UNSTABLE DIAPHYSEAL TIBIAL FRACTURE WITH Handbook of Small Animal Radiology and Ultrasound. John Innes graduated from Liverpool in He gained the certificate in veterinary radiology in and is currently working for a PhD on osteoarthritis in the. TREATMENT OF FEMORAL FRACTURES IN THE DOG use of radiography and improved radiographic used at the University of Queensland Veterinary. Burk RL., Ackerman N. Small animal radiology and ultrasonography. A diagnostic Morgan JP, Leighton RL, Radiology of small animal fracture management. Dept. of Surgery and Radiology, College of Veterinary Science and Animal report the successful surgical management of unstable fracture of ilium and. Stress radiography, where the affected hip is placed down against the radiographic cassette and Manual of Small Animal Fracture Repair and Management. Trauma is the most common cause of fractures in small animals and is Treatment of all pathologic fractures, including those due to neoplasms, can be .. Fracture, either diagnosed or suspected, should be documented by radiography. She received a B.S. in animal and veterinary science from West Virginia University in Diplomate in Radiation Oncology, American College of Radiology Watkins' interests of equine fracture management include: intramedullary interlocking.

[\[PDF\] The Evil Day](#)

[\[PDF\] National Park Service: The First 75 Years Preserving Our Past For The Future](#)

[\[PDF\] Mangans War: A Personal View Of World War II](#)

[\[PDF\] Daughters Of Tunis: Women, Family, And Networks In A Muslim City](#)

[\[PDF\] Nominations Of Harold Furchtgott-Roth, Michael Powell, And Gloria Tristani, To Be Members Of The Fed](#)

[\[PDF\] Why Service Stinks And Exactly What To Do About It](#)

[\[PDF\] Constituting Federal Sovereignty: The European Union In Comparative Context](#)